

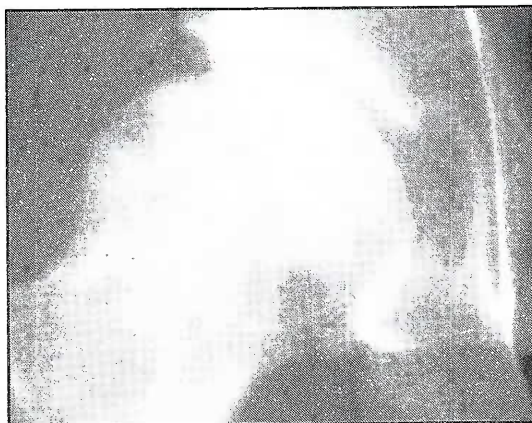Figure 1.

**Avascular necrosis**

Avascular necrosis (AVN) of bone is a rare slowly progressive disease, which can present challenges to the aeromedical practitioner in diagnosis and disposal. A case of AVN is discussed to point out the radiological findings and the value of various investigations that could help arriving at evidence based decision.

**Case Report**

A 23 year flight cadet presented with pain in the right hip, onset August 2002, which lasted for about 4 months till Dec 2002 and thereafter he remained asymptomatic. His general and physical examination did not reveal any abnormality. All biochemical and haematological tests were within normal limits. Initial X-ray of the right hip both AP/Lat showed patchy areas of sclerosis in the subchondral areas of the right femoral head which over the next 6 months progressed, causing irregularity of the articular surface of the femoral head and mild increase in the joint space. MRI of the right hip was suggestive of avascular necrosis of the right femoral head with 25% of the head involved. In the subsequent months the MRI findings showed mild joint effusion with fibrotic changes. Bone scan revealed an area of increased activity at the right femoral head suggestive of ongoing osteoblastic activity. An Orthopedic surgeon consultation and a Human Engineering evaluation found him to be essentially normal with no functional deficit but both opined that he be made unfit for aircrew duties due to the natural history of the disease progressing to severe osteoarthritis with severe functional impairment.

**Discussion**

The term 'avascular necrosis' implies that a segment of bone has lost its blood supply so that the cellular elements within it die. [1] AVN occurs in a number of conditions and usually involves the epiphyses of long bones, such as femoral and humeral heads and femoral condyles, but small bones like talus, scaphoid and navicular bones can also be affected. Early diagnosis and appropriate intervention can delay the need for joint replacement. Patients taking corticosteroids and organ transplant recipients are particularly at risk of developing AVN. Most available data regarding the natural history, pathology, pathogenesis, and treatment of AVN pertain to femoral head necrosis.

**Pathophysiology**

AVN of the hip is the most commonly encountered type in clinical practice. The underlying pathophysiology of the condition is not known but is believed to be caused due to the disruption of the blood supply to the femoral head [2]. Disruption of blood supply and resultant necrosis of marrow, medullary bone and cortex can be caused by the following mechanisms.

- (a) Mechanical interruption of blood supply (e.g. direct trauma leading to fracture, non-traumatic stress, fatigue fracture)
- (b) Thrombotic or embolic occlusion of blood vessels (e.g. fat embolism, sickle cell crisis, decompression sickness)

- (c) Injury to vessel wall (e.g. vasculitis, radiation, infection, connective tissue disease like SLE)
- (d) Pressure on vessel wall (e.g. extravasated blood in marrow, inflammation caused by lipid accumulation in osteocytes, intraosseous hypertension from proliferating Gaucher cells in Gaucher's disease)
- (e) Unknown (e.g. high dose corticosteroid therapy, alcoholism, primary AVN)

Incidence is 1 in 27,200 in western literature. Age of onset depends on the underlying cause. Primary AVN most often occurs during the fourth or fifth decade and is bilateral in 40-80% of cases. No racial predilection exists except for AVN associated with sickle cell disease and HbS.

#### Differential diagnosis

- (a) **Transient osteoporosis of hip.** It is a self limiting cause of hip pain described in middle aged men or in women in their third trimester of pregnancy. Patients present with hip pain and limp in the absence of trauma or infection. The etiology of the condition is unknown, but a neurogenic origin has been proposed, similar to reflex sympathetic dystrophy. Transient osteoporosis of hip resolves spontaneously over a period of 4-10 months. Osteopenia of subchondral cortex is evident on radiography. Bone scan shows diffuse increase in radiotracer uptake in femoral head and frequently in femoral neck. MRI images show diffuse bone marrow edema, which may involve acetabulum and associated hip joint effusion, may precede radiological evidence of osteopenia by several weeks. There is no evidence of the double line sign on MRI as is frequently present in AVN. MRI findings are not characteristic and the primary diagnostic consideration in AVN.
- (b) **Transient bone marrow edema.** This entity is similar to transient osteoporosis in that the condition is a self limited cause of hip pain that resolves over several months. Since the MRI findings and clinical presentation are similar to transient osteoporosis, Hayes et al have proposed that transient bone marrow edema be reserved for those cases in which there is no radiographic evidence of osteopenia. [3]. Again, the etiology of the condition is unknown.

- (c) **Septic arthritis.** Septic arthritis may occur from hematogenous spread of infectious agent or contiguous spread. On MRI images, a joint effusion is present that is bright on T2 images and non-specific in appearance. If septic arthritis is suspected, a joint aspiration must be performed to obtain culture to determine the infectious agent. Underlying bone changes are not typically present, although if the condition is prolonged, evidence of marrow edema may be present (increased signal on T2 images)
- (d) **Stress fracture.** Patients with stress fracture of femoral neck may have similar clinical presentation to patients suspected of AVN. They occur in young patients, usually from overuse and repeated stress in underlying normal bone. Insufficiency fracture occurs in osteoporotic women in whom activity levels are seemingly normal. MRI findings include a diffuse area of increased signal on T2 images with area of the fracture, typically in the femoral neck. This corresponds to edema, and is of intermediate signal on T1 images.

#### Imaging studies

**Radiography.** Radiological findings are unremarkable in the early stages of the disease. In mild to moderate disease, radiography shows sclerosis and changes in bone density. [Fig. 1] In advanced disease, bone deformities like flattening, subchondral radiolucent lines (crescent sign) and collapse of femoral head are evident.

**Classification of AVN.** This is based on conventional radiograph by Ficat and Arlet as follows:-

Stage 0 disease, patients are asymptomatic as shown by normal radiograph and bone scan; only biopsy reveals changes of AVN.

Stage 1 disease, corresponds to patients with pain, decreased range of movement, abnormal bone scan, and normal radiographs.

Stage II disease, radiographs show femoral head osteoporosis with areas of cystic lucency and sclerosis.

Stage III disease there is loss of sphericity with progression to subchondral collapse.

Stage IV disease corresponds to progressive femoral head collapse with normal hip joint space.

Stage V, there are secondary osteoarthritic changes on both the femoral and acetabular sides of the joint, with narrowing. [4]

### Radionuclide Bone Scan

In early AVN, decreased uptake occurs in areas of necrosis. Thereafter an area of increased uptake surrounds the central area of decreased uptake. The phenomenon is known as “Doughnut” sign and indicates reactive zone surrounding the necrotic area [Fig. 2].

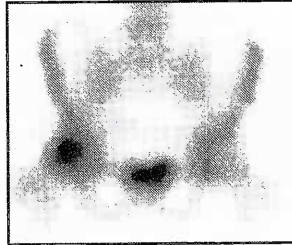


Fig 2: Doughnut sign

However, there are limitations of bone scan. Findings are non specific and results are difficult to interpret if disease is bilateral. For unilateral disease, the healthy side can be used for comparison.

### CT Scan

CT scan shows sclerosis in the central part of the femoral head as an “Asterix” sign [Fig. 3] Changes in the anterior part of the femoral head are easily observed. CT scan is a good modality to assess the extent of disease and calcification, but it is not as sensitive as MRI

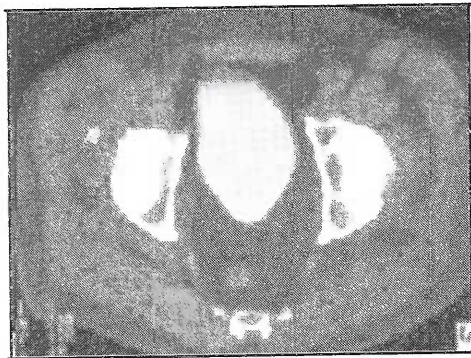


Fig 3: Asterix sign

### MRI Findings

AVN is diagnosed when a peripheral band of low signal is present in all imaging sequences, typically in the superior portion of the femoral head, outlining a central area of necrosis.

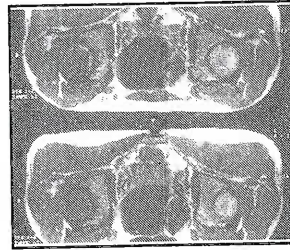

Fig 4: Double-line sign

On conventional T2 sequences, the inner border of the peripheral band shows high signal in 80% of cases. This is called the “Double - line” sign of AVN, and is considered pathognomonic. [Fig. 4] It has been reported that the inner bright signal is due to the reactive interface or granulation tissue between the infarcted and normal marrow. T2 sequences and inverse recovery sequences frequently demonstrate associated hip effusion. Increased joint effusion is commonly associated with AVN, and its presence does not indicate a septic joint effusion. The patients present with pain due to this effusion, rather than the longstanding process of AVN. Pain associated with joint effusion may be due to the distension of joint capsule by the fluid.

### Staging

MR staging of AVN is based on the signal intensity of the center of the marrow inside the dark line of necrosis. Radiological occult AVN will generally be depicted on MRI as any classes of A to C. Unlike the radiographic staging, MR classes have little predictive value regarding the prognosis for collapse of the femoral head. Mitchell has developed an MR imaging classification based on the appearance of the central zone [5]. This area may simulate fat (Class A: high signal on T1 weighted images, intermediate on T2 - weighting), blood (Class B: high signal on T1 and T2 images), fluid (Class C: low signal on T1 images and high intensity on T2 images) or fibrous tissue (Class D: low signal on all images).

### Aeromedical Concerns

Natural history of AVN, involves subchondral necrosis, subchondral fracture and collapse of bone, deformity of the articular surface and osteoarthritis. In later stages, sclerosis and total destruction of the joint may occur. The factors affecting the rate of progression are etiology, body weight and age of onset. Prognosis depends on the disease stage at the time of diagnosis and on any underlying conditions. Cases of idiopathic AVN progressed slower than when the osteonecrosis

was associated with steroid or alcohol. More than 50% of the patients require surgical treatment within 3 years of diagnosis. Half of patients with subchondral collapse of femoral head develop AVN in contralateral hip.

### **Disposal**

In the case being discussed, disposal was straight forward as the aircrew was a cadet and had yet to start his flying career. The problem of detection of idiopathic AVN in a trained serving aircrew presents much more of a problem. The absence of abnormal clinical findings after the initial period of pain could lead to full function of the effected joint. However the necrosed bone would be weak and could fracture with unrestricted physical activity. The probability of a safe landing after ejection or crash landing would also be compromised. Thus all cases of avascular necrosis of the hip should be advised restricted physical activity and should be assessed unfit for all types of aircrew duties.

Contributed by: Wg Cdr VG Vasishta  
Surg Cdr L J Pinto  
Gp Capt R K Garg  
Dr S Baxla

### **References**

1. Avascular Necrosis: Osteochondritis, misc bone lesions. In David Sutton, editor. Textbook of Radiology and imaging. 6th Edition. Churchill Livingstone Inc, New York, 1998: 65-83.
2. Avascular Necrosis of the Hip. In Bailey and Love, editor. Short Practice of Surgery. 23rd Edition. Publisher 376-378.
3. Hayes CW, Conway WF, David WW: MR Imaging of Bone Marrow Edema Pattern, Transient Osteoporosis, Transient Bone Marrow Edema Syndrome or Osteonecrosis. Radiographics 13: 1993:1001-1011.
4. Mark D Murphy. The Hip. In John R Haaga, Charles F Lanzieri, editors. Computed Tomography and Magnetic Resonance Imaging of Whole Body. 3rd Edition, volume II. 1448-1473.
5. Mitchell DG, Rao VM, Dalinka MK, et al: Femoral Head AVN: correlation of MR Imaging, Radiographic Staging, Radionuclide Imaging and Clinical Findings. Radiology 162:1987: 709-715.