



Original Article

Lumbosacral transitional vertebra in military aviation candidates: A cross-sectional study

R Vaidya¹, M Bhatia²

¹Specialist in Community Medicine and Dean, Armed Forces Medical College, Pune, India, ²Radiologist, Department of Radiodiagnosis, Air Force Central Medical Establishment, IAF, New Delhi, India.



***Corresponding author:**
Dr M Bhatia, MBBS, MD
(Radiodiagnosis),
Department of Radiodiagnosis,
Air Force Central Medical
Establishment, New
Delhi-110010, India.

drmukulbhatia@hotmail.com

Received : 17 July 2020
Accepted : 22 December 2020
Published : 06 August 2021

DOI
10.25259/IJASM_50_2020

Quick Response Code:



ABSTRACT

Introduction: Lumbosacral transitional vertebra (LSTV) is a common anomaly of the lumbosacral junction with a prevalence of 4–35.9% in various studies. Plain radiography of the spine in anteroposterior and lateral projections is done for the evaluation of the spine in candidates coming for medical evaluation for flying duties in the armed forces.

Material and Methods: An observational study was conducted on the whole spine series of radiographs done at a medical selection establishment. The study population included candidates reporting to the establishment for medical examination to ascertain fitness for flying duties. In a small subset of this study population having LSTV, the Ferguson's view was done to better delineate the lumbosacral junction.

Results: The analysis revealed a total 148 cases of LSTV with a prevalence of 13.9%. Ferguson's view, undertaken among 30 doubtful cases, confirmed the presence of LSTV in 27 cases. Type IIa was observed to be the most common pattern of LSTV followed by Type IIIb. As per the existing policy, 63.8% of candidates with LSTV were considered unfit for flying duties.

Conclusion: Flying duties in the armed forces require the highest standard of physical fitness. LSTV is a very common finding during the evaluation of candidates and it is appropriate that the cases of LSTV be evaluated thoroughly. In doubtful cases of LSTV, the Ferguson's view is a useful supplementary view as it clearly delineates the lumbosacral junction.

Keywords: Lumbosacral transitional vertebra, Military aviation, Ferguson's view

INTRODUCTION

Lumbosacral transitional vertebra (LSTV) is a common congenital spinal anomaly or rather a spectrum of anomalies involving the fifth lumbar and/or the first sacral vertebra. Castellvi *et al.* have classified LSTV into four subtypes.^[1] These four subtypes incorporate all the types of lumbarization or sacralization that may occur at the lumbosacral junction. Various studies have reported a prevalence rate of 4–35.9% for LSTV.^[2] Mario Bertolotti first described the morphologic characteristics of LSTV and its association with low back pain (LBP) in 1917 and this association has, therefore, been termed as Bertolotti Syndrome.^[3] Certain types of LSTV are associated with alterations in the biomechanics of the spine and the paraspinal structures leading to LBP. The presence of these types of LSTV in a candidate makes him/ her unfit for aviation duties. At present, no study has been published on the prevalence of LSTV among candidates

This is an open-access article distributed under the terms of the Creative Commons Attribution-Non Commercial-Share Alike 4.0 License, which allows others to remix, tweak, and build upon the work non-commercially, as long as the author is credited and the new creations are licensed under the identical terms.

©2021 Published by Scientific Scholar on behalf of Indian Journal of Aerospace Medicine

being evaluated for fitness for aviation duties. The primary objective of this study was to determine the prevalence of LSTV among flying aspirants and secondarily, to ascertain the utility of Ferguson's view as a supplementary radiography in the evaluation of the lumbosacral junction to identify the condition.

MATERIAL AND METHODS

Type of study

An observational cross-sectional study which included the review of the whole spine radiographs of candidates reporting to a premier Indian Air Force (IAF) selection establishment for their medical evaluation for flying duties in the Armed Forces.

Study population

The participants consisted of male and female candidates between the age group of 16 and 33 years, who reported to our establishment for their medical examination, to ascertain fitness for military aviation. The candidates included ab-initio candidates who were seeking entry into the flying branch of the IAF as well as combatant members of the Armed Forces who were being evaluated for fitness for aviation duties.

Methodology

Permission of the establishment was obtained for analyzing the data and identity of the participants has not been revealed in the study. Radiography of the spine was done as per standard protocol after obtaining an informed consent. In addition to the standard anteroposterior (AP) and lateral views, Ferguson's view was added after April 2019, in a small group of candidates where there was ambiguity with respect to the presence and type of LSTV. The Ferguson's view is a variation of the standard AP view and was done in the supine AP projection with a 30° cranial tilt to the tube head. The cranial tilt to the tube makes the central ray perpendicular to the lumbosacral junction, delineating it clearly.

Image analysis

All images and available reports for a period of 2 years between August 2017 and August 2019 were reviewed on the workstation by an experienced radiologist. Vertebrae were counted in all images from C2 downward. The craniocaudal width of the transverse process, with a threshold of greater than 19 mm, was measured using the digital caliper on a picture archiving and communication system. The presence of articulation or complete fusion of the transverse process with the sacrum was evaluated on AP radiograph of the lumbosacral spine. In cases where ambiguity was noted on an AP radiograph, Ferguson's view was done to evaluate the lumbosacral junction. The data

were analyzed as per the standard internationally acceptable Castellvi classification [Table 1].

RESULTS

The study included retrospective and prospective analysis of AP and lateral radiographs of the whole spine of candidates done for a period of 2 years. Radiographs of a total of 1071 candidates were examined, out of which 1031 (96.3%) were male and 40 (3.7%) were female. The youngest candidate was 16 years old while the oldest was 33 years old. The analysis revealed a total 148 cases of LSTV with a prevalence of 13.9%.

Ferguson's view was done for a total of 30 candidates for better evaluation of LSTV, whenever there was ambiguity on AP radiographs. Out of these 30 cases, the presence and type of LSTV was confirmed by Ferguson's view in 27 cases while in the remaining 3 cases, LSTV was excluded.

Further analysis of the data revealed that Type IIa was the most common pattern identified followed by Type IIIb. The number of candidates in various subtypes of LSTV is given at Table 2. As per the existing guidelines, 36.2% of cases (Type 1a, 1b, and IIIb) were considered fit, whereas rest (63.8%) were considered unfit for flying duties.

DISCUSSION

LSTV is a spectrum of common congenital anomalies with a prevalence rate of 4.0–35.9%.^[2] This wide variation in the prevalence of this entity is due to the varying diagnostic

Table 1: Castellvi classification of lumbosacral transitional vertebrae.^[1]

Type Ia (Unilateral)	Broad, dysplastic transverse process with height More than 19 mm
Type Ib (Bilateral)	Incomplete sacralization/lumbarization with a pseudoarthrosis between the transverse process and the sacral ala
Type IIa (Unilateral)	Complete sacralization/lumbarization with bony fusion between the enlarged transverse process and the sacral ala
Type IIb (Bilateral)	Mixed: Type II on one side, III on other
Type IIIa (Unilateral)	
Type IIIb (Bilateral)	
Type IV	

Table 2: LSTV subtypes.

Castellvi subtype	Males	Females
IA	13	1
IB	12	0
IIA	34	1
IIB	27	1
IIIA	17	0
IIIB	30	2
IV	10	0
Total	143	5

criteria as well as the different imaging modalities and techniques used to evaluate it, as also the clinical setting in which the anomaly is picked up. It is one of those clinical conditions which may have been underreported, as it is most often reported as an incidental finding. When it is the fifth lumbar vertebra which fuses or assimilates with the sacrum, the condition is called sacralization, whereas, the separation of the S1 segment from the rest of the sacrum is called lumbarization. It is postulated that the development of transitional vertebra depends on the weight transmitting ability of the sacrum and the surface area of its articular surface with the ilium. Sacralization or addition of a vertebra results when this area is inadequate, while if the surface area is more, release of a sacral vertebra or lumbarization occurs.^[4] Both the processes occur at a very rudimentary stage in the development of the sacrum. Increase incidence of LSTV in some families suggests a genetic component. HOX10/HOX11 is genes influencing the vertebral segmentation and mutations in these genes may play a role in the formation of LSTV.^[5]

The asymptomatic radiological conditions detected during entry medicals of the flying aspirants are given in the Indian Air Force Publication, Manual of Medical Examinations and Medical Boards, 5th edition. As per the existing guideline,^[6] cases of LSTV with complete bilateral sacralization or lumbarization are only considered fit for flying duties. Thus, identification of the condition and appropriate classification becomes important. The classification of LSTV is generally followed as given by Castellvi *et al.* in 1984. It is based on the varying degree of articulation between the sacral ala and the transverse process [Table 1]. The classification, though widely followed, does not provide information regarding the accurate numbering of the involved segment. There are other morphological changes that are observed in a case of transitional vertebra. These include squaring of the upper sacral segment when sacralized and wedging of the sacral segment when lumbarized.^[7] This “squaring” or “wedging,” however, is not enough to diagnose a transitional vertebra as there is considerable overlap with the normal variants. Reduction in the disc height is noted when a lumbar vertebra is sacralized, and similarly, there may be an increase in the disc space between S1 and S2 when the former is lumbarized.^[8] Changes in the facet joints are observed at the lumbosacral junction in cases of LSTV. It may be hypoplasia or aplasia of the facet joints which may be unilateral or bilateral, asymmetrical, or symmetrical.^[9] While identifying the condition in our study, all the above variables were taken into consideration. However, the analysis was done as per Castellvi classification.

Our study involved evaluation of 1071 candidates in the age group of 16–33 years by radiography of the whole spine in the AP and lateral projection. The Ferguson's view was added in the prospective part of the study, being done as a supplementary view, to confirm the presence and characterize the type of LSTV. The condition has been

classically described on Ferguson's projection which is AP radiographs with 30° cranial angulation. This view is an established view to delineate the lumbosacral junction.^[10] Other modalities such as CT and MRI are also useful for delineation of LSTV but are not included in the evaluation of candidates. In our study group, we did the Ferguson's view for 30 candidates. There was an element of doubt in these cases with respect to the presence and type of LSTV. In all these candidates, the Ferguson's view resolved the diagnostic dilemma by confirming the type of LSTV in 27 cases while excluding it in 3 cases. Figures 1 and 2 illustrate the utility of this view in the evaluation of LSTV. The prevalence of LSTV in our subset of population was 13.9% which is in accordance with the reported prevalence in the literature.^[2]

The identification of this condition during radiological examination of the candidates for flying duties is important. This is because of the following reasons; (a) few types of LSTV are not considered fit for flying duties, (b) ability of the

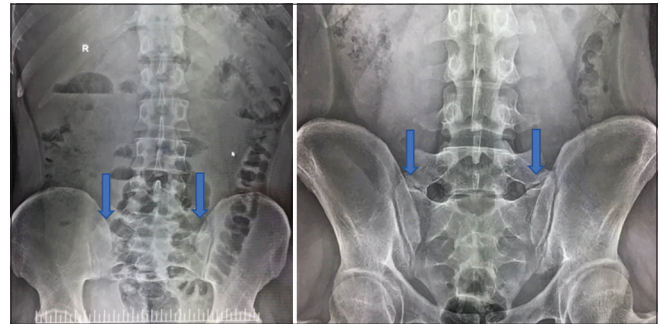


Figure 1: Anteroposterior (AP) and Ferguson's view done in a candidate. It is difficult to ascertain the type of lumbosacral transitional vertebra (LSTV) based on the AP projection alone. The Ferguson's view clearly delineates the bilateral pseudoarthrosis making it LSTV IIb. The arrows point to the articulation between the transverse process of L5 and the sacral ala.

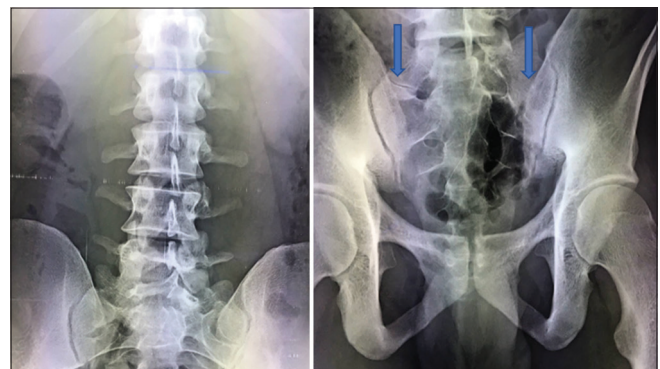


Figure 2: Anteroposterior and Ferguson's view in a candidate. The presence and type of lumbosacral transitional vertebra (Castellvi Type IV: Complete fusion on the left and pseudoarthrosis on the right) is clearly delineated on the Ferguson's view. The arrows point to the articulation between the transverse process and the sacral ala.

spine to withstand aviation stress is suspect in few variants, and (c) there may be a possibility of development of backache in later part of the flying carrier.

As mentioned earlier,^[6] candidates with incomplete unilateral or bilateral sacralization or lumbarization and complete unilateral sacralization or lumbarization are being declared unfit while those with bilateral complete sacralization or lumbarization are being declared fit. As per the Castellvi classification, this translates to Type Ia, Ib, and IIIb being fit while types IIa, IIb, IIIa, and IV are unfit. The basic premise is that symmetric, bilateral, complete assimilation or separation is fit for aviation duties, whereas asymmetry of articulation between the two sides and presence of incomplete articulation or pseudoarticulation between the transverse process and the sacral ala are grounds for making a candidate unfit. Based on the above criteria, 36.2% of candidates were considered fit and 63.8% unfit in our study.

Spine is the most important part of human body which is vulnerable to aviation stress. With LSTV, when the articulations are incomplete or unilateral, spinal geometry becomes unstable. Further, this results in alteration of the transmission characteristics of the forces in case of ejection from a fighter aircraft when there is dynamic overloading of the spine. This may result in increased probability of a spinal injury in case of an ejection.

The association of LSTV with low backache was described almost over 100 years back by Bertolotti. It is postulated that the back pain in a case of LSTV may be due to various causes. It may originate from the incomplete articulation between the transverse process and the sacral ala, from the contralateral facet joint when the transitional vertebral vertebra is unilateral. It may also originate due to the early degeneration of the disc, cephalad to the transitional segment or may arise from the neural compromise caused by the hypertrophic transverse process.^[11] Hence, the possibility of development of backache in future cannot be ruled out specifically on exposure to vibration and awkward flying posture of the helicopter as well as cramped sitting and repetitive G loading of fighter flying.

Our study had some limitations. The candidates coming to us would not volunteer any information with respect to back pain as it would have made them outright unfit for aviation duties. Another limitation was the lack of Ferguson's view in cases done before April 2019. Further, we could not access data on other types of radiological abnormalities that constituted rejection of flying aspirants; hence, the overall percentage of rejection due to LSTV could not be analyzed. In addition, the data from the other two boarding centers were not accessible to us so we had to limit the study to our establishment only.

CONCLUSION

The prevalence of LSTV on analysis of radiographs of flying aspirants over a period of 2 years was found to be

13.8%. Out of this, 63.8% were rejected as per the existing guidelines. The Ferguson's view was found to be a useful view for cases of suspected LSTV to identify and characterize the transitional vertebrae and hence, it is strongly recommended that this view be resorted to in the evaluation of LSTV as a supplementary view.

Declaration of patient consent

Participant's consent not required as participants identity is not disclosed or compromised.

Financial support and sponsorship

Nil.

Conflicts of interest

There are no conflicts of interest.

REFERENCES

1. Castellvi AE, Goldstein LA, Chan DP. Lumbosacral transitional vertebrae and their relationship with lumbar extradural defects. *Spine* 1984;9:493-5.
2. Matson DM, MacCormick LM, Sembrano JN, Polly DW. Sacral dysmorphism and lumbosacral transitional vertebrae (LSTV) review. *Int J Spine Surg* 2020;14:S14-9.
3. Elster AD. Bertolotti's syndrome revisited. Transitional vertebrae of the lumbar spine. *Spine* 1989;14:1373-7.
4. Mahato NK. Morphological traits in sacra associated with complete and partial lumbarization of first sacral segment. *Spine J* 2010;10:910-5.
5. Paik NC, Lim CS, Jang HS. Numeric and morphological verification of lumbosacral segments in 8280 consecutive patients. *Spine* 2013;38:E573.
6. IAP. Assessment of candidates for flying and ground duty branches and airmen aircrew. In: *Manual of Medical Examinations and Medical Boards*. 5th ed. Mumbai: IAP; 2020. p. 115.
7. Wigh RE, Anthony HF. Transitional lumbosacral discs. Probability of herniation. *Spine* 1981;6:168-71.
8. Nicholson AA, Roberts GM, Williams LA. The measured height of the lumbosacral disc in patients with and without transitional vertebrae. *Br J Radiol* 1988;61:454-5.
9. Mahato NK. Facet dimensions, orientation, and symmetry at L5-S1 junction in lumbosacral transitional states. *Spine* 2011;36:E569-73.
10. Jancuska J, Spivak J, Bendo J. A review of symptomatic lumbosacral transitional vertebrae: Bertolotti's syndrome. *Int J Spine Surg* 2015;9:42.
11. Konin GP, Walz DM. Lumbosacral transitional vertebrae: Classification, imaging findings, and clinical relevance. *Am J Neuroradiol* 2010;31:1778-86.

How to cite this article: Vaidya R, Bhatia M. Lumbosacral transitional vertebra in military aviation candidates: A cross-sectional study. *Indian J Aersp Med* 2021;65(1):29-32.